




## **Clinical Pearls: Unraveling the Secrets of Imaging Studies**

---

David M. Glick, DC, DAIPM, CPE



## **Conflict of Interest and Disclosures**

---

- Nothing to Disclose



## Learning Objectives

---


- Describe the clinical utility and limitations of key imaging studies for the differential diagnosis of pain pathologies.
- Identify how reliance upon such studies alone can adversely influence the outcome of patient treatment.
- Explain strategies to enhance the clinical yield of pain diagnostic studies.

**PainWeek**

## When More Medicine is Less

---

- Nine United States specialty societies representing 374,000 physicians developed lists of *Five Things Physicians and Patients Should Question*
- [American Academy of Allergy, Asthma & Immunology](#)
- [American Academy of Family Physicians](#)
- [American College of Cardiology](#)
- [American College of Physicians](#)
- [American College of Radiology](#)
- [American Gastroenterological Association](#)
- [American Society of Clinical Oncology](#)
- [American Society of Nephrology](#)
- [American Society of Nuclear Cardiology](#)



**PainWeek**

[http://choosingwisely.org/?page\\_id=13](http://choosingwisely.org/?page_id=13)

## Choosing Wisely (Initiative of ABIM Foundation):

---

- Not only are many procedures unnecessary, some are actually harmful and can lead to mistaken diagnosis or endless rounds of follow-up testing when nothing is wrong.
- *“Over testing and over treating is harming people and unethical.”* (Dr. Glen Stream President American Academy of Family Practice Physicians & Panel member)



[http://choosingwisely.org/?page\\_id=13](http://choosingwisely.org/?page_id=13)

## Medical Necessity of Imaging for LBP

---

- Low back pain is the fifth most common reason for all physician visits.
- Don't do imaging for low back pain within the first six weeks, unless red flags are present.
  - Red flags include, but are not limited to, severe or progressive neurological deficits or when serious underlying conditions such as osteomyelitis are suspected. Imaging of the lower spine before six weeks does not improve outcomes, but does increase costs.



[http://choosingwisely.org/?page\\_id=13](http://choosingwisely.org/?page_id=13)



## MRI and CT Scans for Headaches

- Don't do imaging for uncomplicated headache.

“Imaging headache patients absent specific risk factors (such as loss of vision, seizures, etc) for structural disease is not likely to change management or improve outcome. Those patients with a significant likelihood of structural disease requiring immediate attention are detected by clinical screens that have been validated in many settings. Many studies and clinical practice guidelines concur. Also, incidental findings lead to additional medical procedures and expense that do not improve patient well-being.”



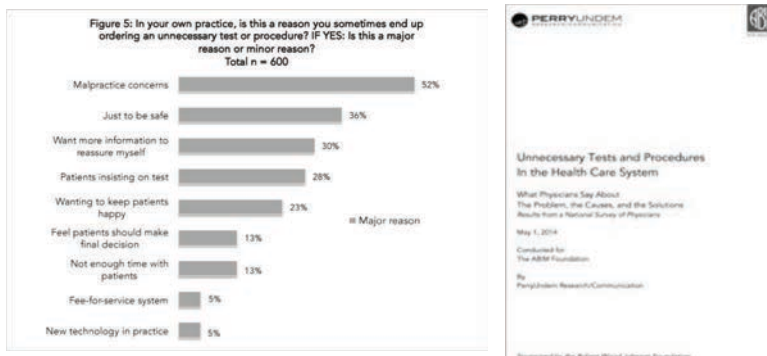
**PainWeek** [p://choosingwisely.org/?page\\_id=13](http://choosingwisely.org/?page_id=13)

## Choosing Wisely Update

- 72 Societies and 17 community groups have joined the initiative.
- Over 450 recommendations (over 66 lists).
- Hundreds of potentially unnecessary medical tests and treatments have been identified to date.
- Several societies have released 2<sup>nd</sup> and 3<sup>rd</sup> lists.
- Estimated 5 billion in potential savings for unnecessary testing.
- 400 Main stream articles/20,000 blogs or Pt stories about unnecessary tests or treatments.

**PainWeek**

## Choosing Wisely Update



**PainWeek**

[http://www.choosingwisely.org/wp-content/uploads/2014/04/042814\\_Final-Choosing-Wisely-Survey-Report.pdf](http://www.choosingwisely.org/wp-content/uploads/2014/04/042814_Final-Choosing-Wisely-Survey-Report.pdf)

## Most Important Tools for Differential Diagnosis...

- History
- Clinical Examination
- Experience of Clinician

**PainWeek**

## Adverse Factors Affecting Physical Diagnosis

---

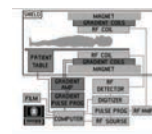
- Limitations of Time
  - *Volume of patients may limit face-to-face time with clinician.*
  - *Reimbursements tend to devalue clinical component.*
- Reliance Upon Technology
  - *MRI shows disc herniations so that must be the cause of the patient's neck pain.*
- Clinical Experience
  - *Has the clinician evaluated patients with similar symptoms before*

**PainWeek**

## MRI - Magnetic Resonance Imaging

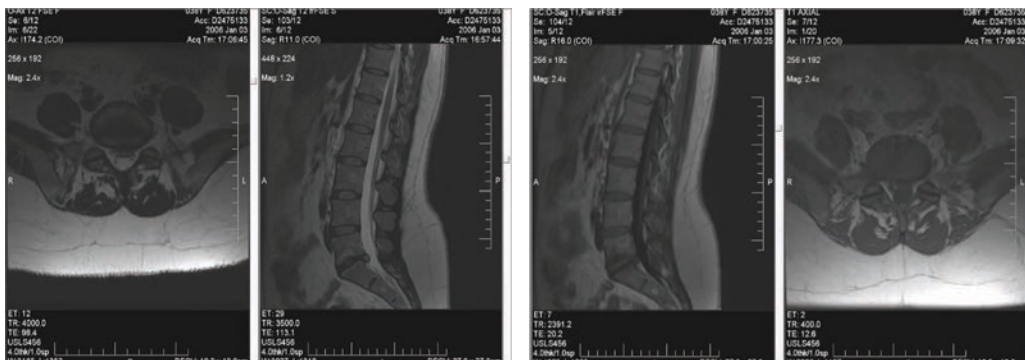
---

- Uses a powerful magnetic field to align the hydrogen atoms in water in the body. Radio frequency (RF) fields are used to energize hydrogen nuclei (protons). When the field is turned off, energy is released as the protons return to their resting state. This energy is recorded by the scanner. The position of protons in the body can be determined by applying additional magnetic fields (using gradient coils) during the scan, which allows an image of the body to be created.
- Contrast between different types of body tissue is created by changing the parameters on the scanner. Diseased tissue, such as tumors, can be detected because the protons in different tissues return to their equilibrium state at different rates.



**PainWeek**

Novelline, Robert. *Squire's Fundamentals of Radiology*. Harvard University Press. 5th edition. 1997



- On a T2-weighted scan, water- and fluid-containing tissues are bright and fat-containing tissues are dark, the reverse is true for T1.
- Damaged tissue tends to develop edema, which makes a T2-weighted sequence sensitive for pathology



## Nerve Root Compression

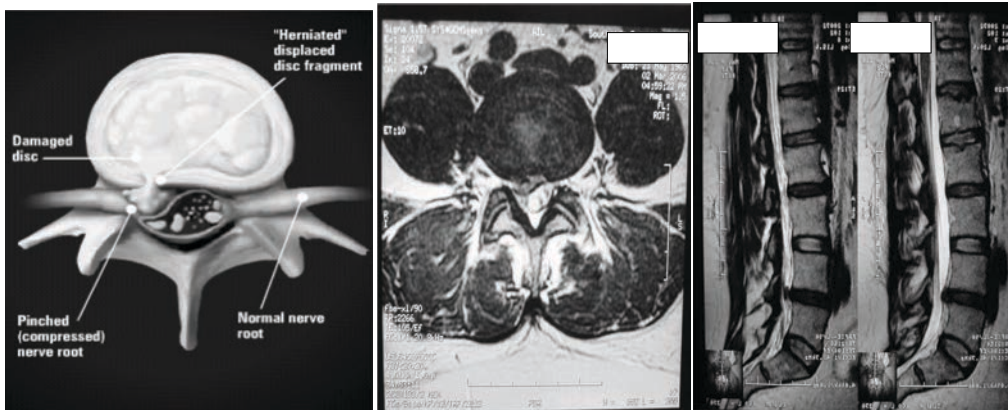
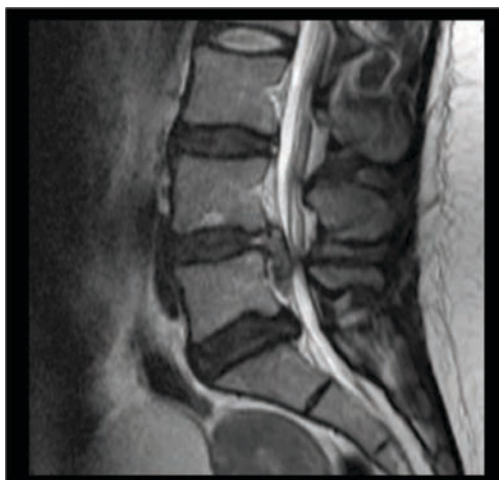

Image © Swarm Interactive [www.swarminteractive.com](http://www.swarminteractive.com)

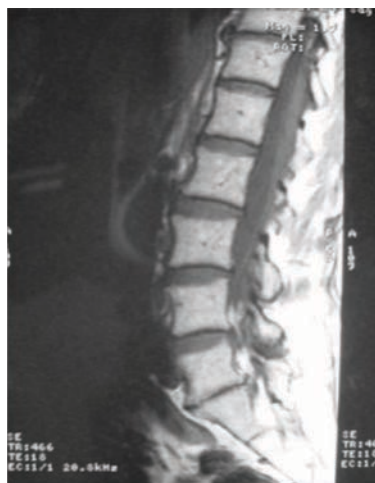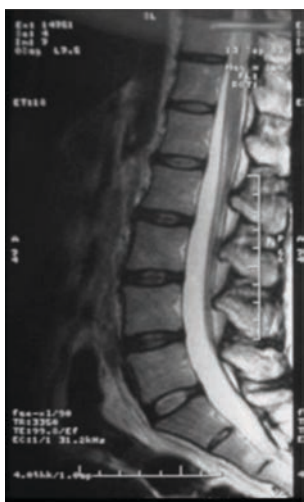## Putting Knowledge to the Test...



Surgical or Non-surgical?  
Axial back pain without  
radicular symptoms

**PainWeek.**

## Which patient is suffering from severe chronic low back pain?

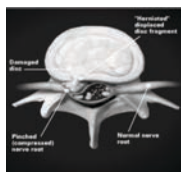


**PainWeek.**

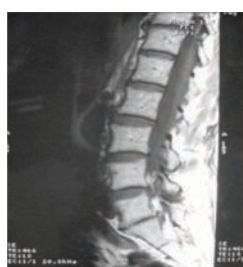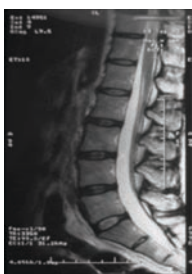Image © Swarm Interactive [www.swarminteractive.com](http://www.swarminteractive.com)



## Clinical Pearl



MRI may demonstrate disc compression of a nerve, but current technology ***does not*** describe inflammation of a nerve (radiculitis).



Which patient is suffering from severe chronic low back pain?

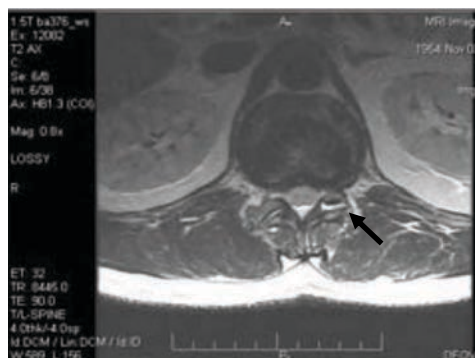
While providing valuable structural, they do not necessarily reflect whether a pathology is clinically relevant.



Image © Swarm Interactive [www.swarminteractive.com](http://www.swarminteractive.com)

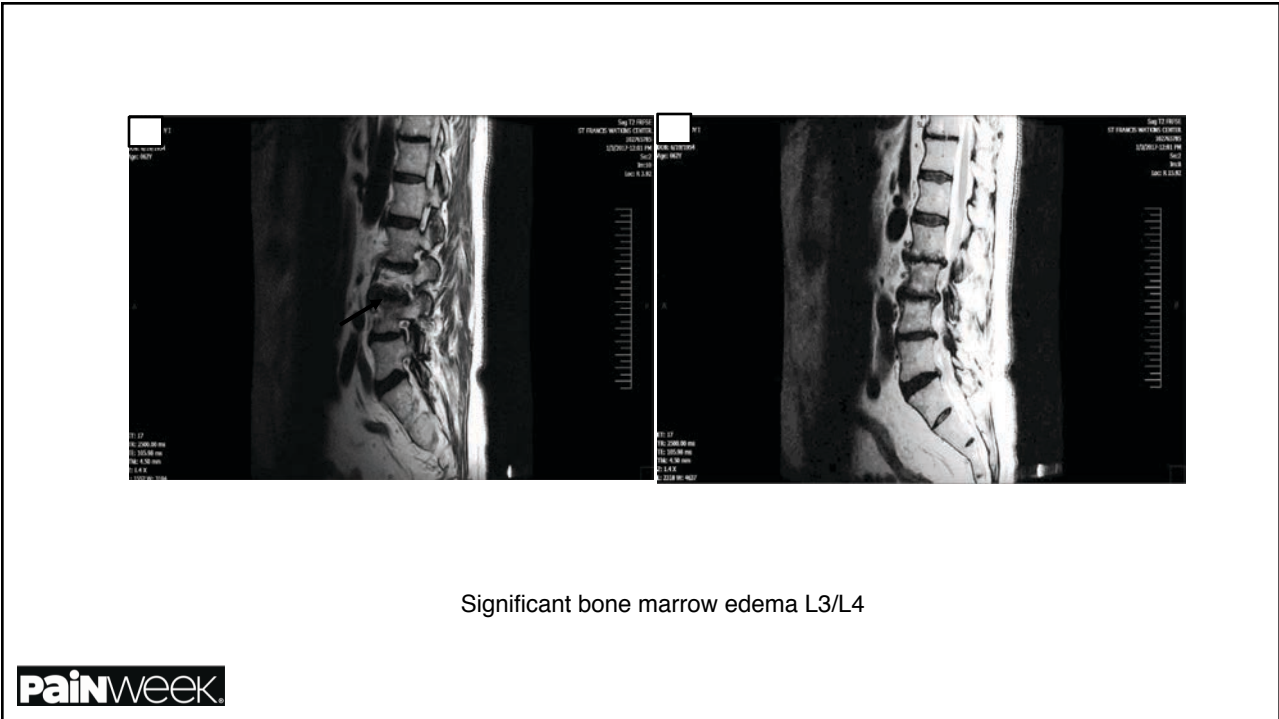
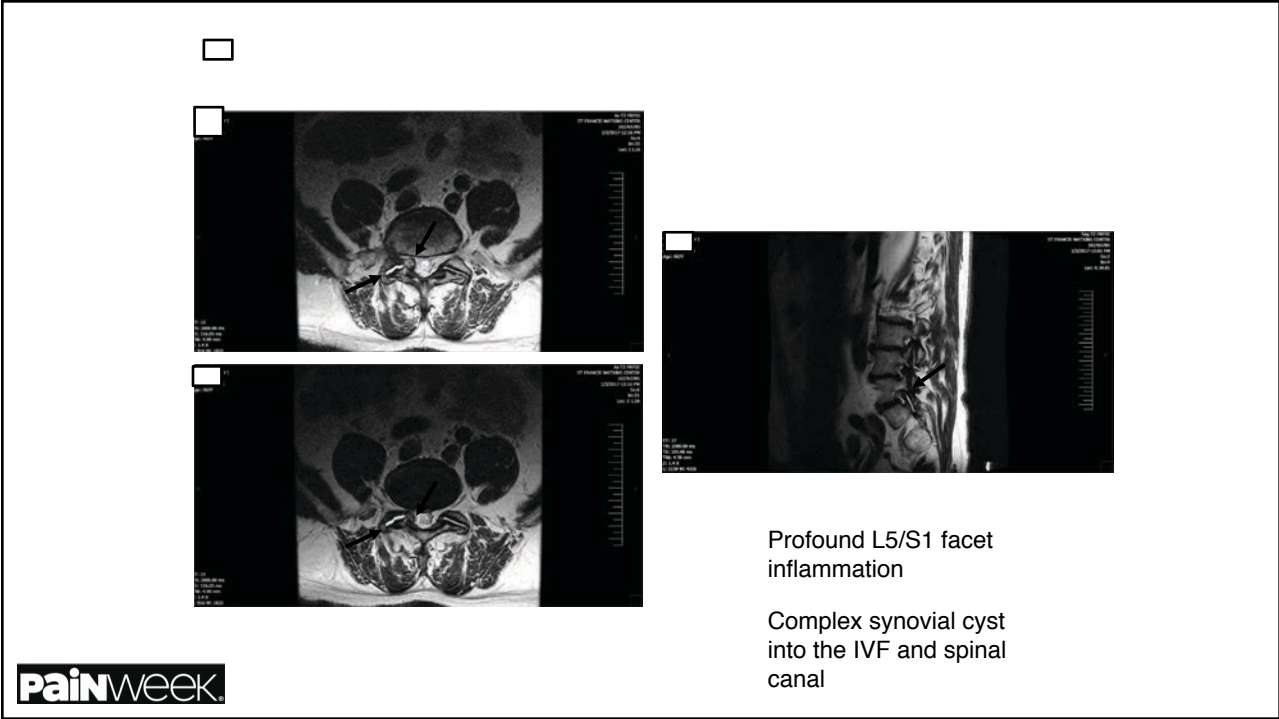
## Clinical Pearl

Facet joint inflammation



The individual reading the MRI or other imaging study is often not clinically familiar with the patient





Page 1 of 2

Order History  
Procedure: MRI LUMB SPINE WO CONT (T2148)  
Accession Number: 01032017 12:30 PM  
Order Number: 102765785  
Order Date: 30/09/2016

Ordering Diagnosis: Lumbosacral radiculopathy (M54.17 (ICD-10-CM))  
Reason for Exam: Lumbosacral radiculopathy  
Performing Department: Walkers Imaging Center MRI Department  
Patient Class: OUTPATIENT HEALTHSOURCE

Study Result  
Indication: Lower back pain with right leg numbness

Exam: MRI of the lumbar spine. Sequences include sagittal and axial T1 and T2-weighted images. Sagittal STIR.

Contrast: None

Findings: There is a borderline dystrophic disc of the lumbar spine. There is multilevel endplate degenerative change. No fracture or marrow replacement. Cord stenosis is within normal limits. Paraspinal soft tissues are within normal limits.

T12-L1: No stenosis  
L1-L2: No stenosis  
L2-L3: There is disc height loss with degeneration of this disc. There is a small disc bulge. There are bilateral facet degenerative changes. There is narrowing of the left subarticular zone with mild to moderate left and mild right foraminal narrowing.  
L3-L4: There is disc height loss with degeneration of this disc with a diffuse disc bulge. There are bilateral facet degenerative changes. There is prominence of the epidural fat. Canal stenosis is moderate in conjunction with the epidural fat. Canal stenosis is moderate to moderate right foraminal narrowing. Spontaneous with moderate left and mild-to-moderate right foraminal narrowing.  
L4-L5: There are bilateral facet degenerative changes with thickening of the

Printed on 3/15/2017 10:04:56 AM

Page 2 of 2

ligamentum flavum and a slight bulge. Canal stenosis is mild with narrowing of the bilateral subarticular zones. There is mild to moderate right greater than left foraminal narrowing.

L5-S1: There are bilateral facet degenerative changes right greater than left with a small disc bulge asymmetric to the right. This results in narrowing of the right subarticular zone and mild to moderate right foraminal narrowing.

IMPRESSION  
Impression:  
1. Multilevel degenerative change detailed by level above most significant at L3-L4.

Result History  
MRI LUMB SPINE WO CONT (Order #353941085) on 3/30/2017 - Order Result History Report

There are no end exam questions for this visit.



Signing Date/Time: [Redacted]  
Signed by: [Redacted]  
Interpreted/Read by: [Redacted]

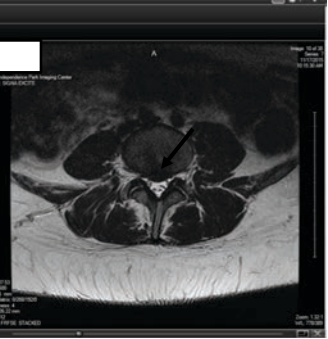
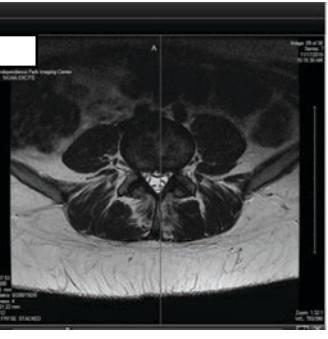
STATEMENT OF CONFIDENTIALITY NOTICE  
This facsimile transmission is intended to be confidential to the individual(s) and/or entity to whom it is addressed. It may contain information of a financial and/or Confidential Nature which is subject to the signed recipient. If you are unable to deliver this communication to the intended recipient, do not read, copy or use the information contained within this transmission, or allow it to be read, copied or utilized in any manner by any other person(s). Should this transmission be received in error, please notify the above named sender immediately by telephone.

THIS DOCUMENT WAS SIGNED ELECTRONICALLY. A COPY OF THIS DOCUMENT IS ON-LINE IN THE SIGNER'S EMR.  
BY ELECTRONICALLY SIGNING THIS REPORT, I THE SIGNER PHYSICIAN, ATTEST THAT I HAVE PERSONALLY REVIEWED THE IMAGES FOR THE ABOVE EXAMINATIONS AND AGREE WITH THE FINDINGS AS DOCUMENTED ABOVE.

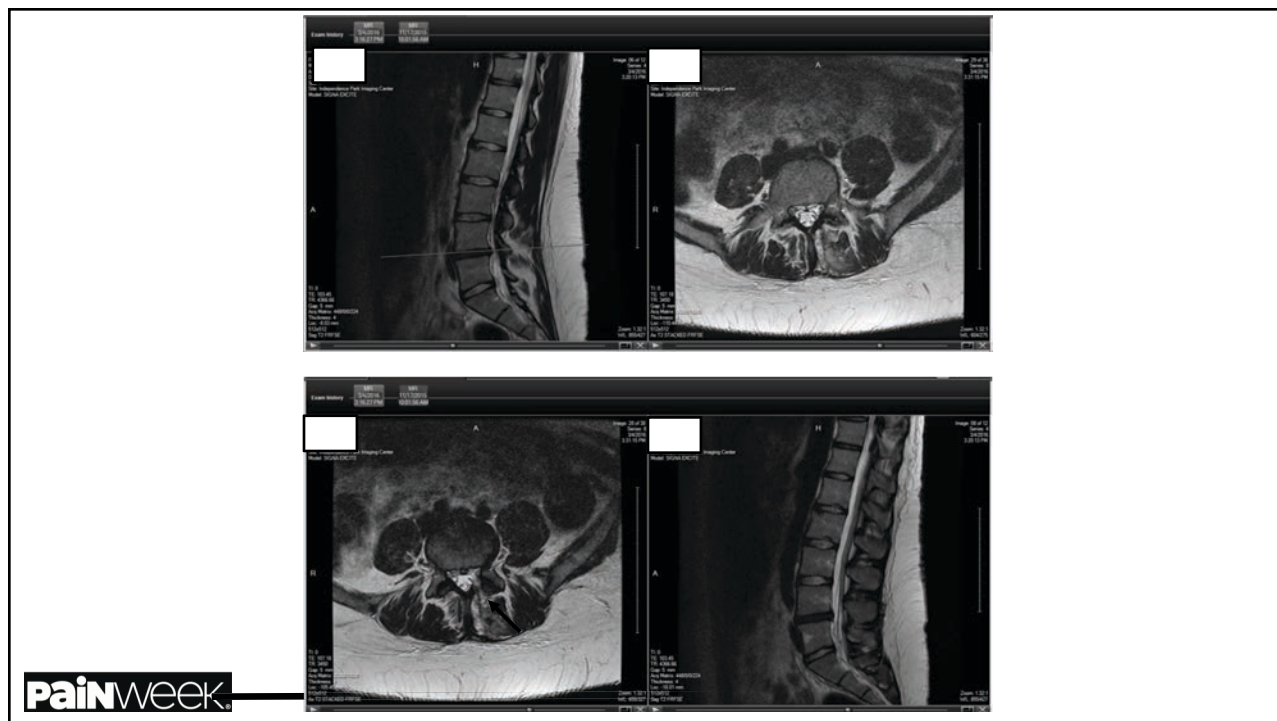
Page

Painweek.

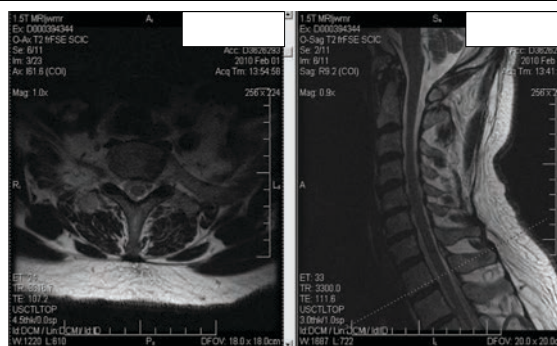
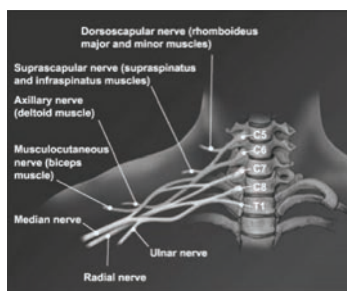
Painweek.



**PainWeek**

## Clinical Pearl

Always request axial images to include C8 & T1 roots on order for Cervical MRI



- Brachial Plexus is C5-T1 spinal nerve roots
- All intrinsic muscles of the hand are innervated by C8/T1, as are most muscles for grip
- If upper extremity symptoms extend to hand or include decrease grip strength, then there is a high likelihood C8 or T1 is involved
- Most Cervical MRIs do not image the T1 root, and many do not include C8

**PainWeek**

Brachial plexus image © Medcom studios – Renee Cannon [www.medcomstudios.com](http://www.medcomstudios.com)

## MRI of the lumbar spine in people without back pain.

---

On MRI examination of the lumbar spine, many people without back pain have disc bulges or protrusions but not extrusions. Given the high prevalence of these findings and of back pain, the discovery by MRI of bulges or protrusions in people with low back pain may frequently be coincidental.

***.... Thirty-six percent of the 98 asymptomatic subjects had normal discs at all levels. With the results of the two readings averaged, 52% of the subjects had a bulge at least one level, 27% had a protrusion, and 1% had an extrusion. 38% had an abnormality of more than one intervertebral disc.***

- Jensen MC, Brant-Zawadzki MN, Obuchowski N, Modic MT, et. al., Magnetic resonance imaging of the lumbar spine in people without back pain. N Engl J Med. 1994 Jul 14;331(2):69-73. (PMID: 8208267)



## The Use of Lumbar Spine Magnetic Resonance Imaging in Eastern China: Appropriateness and Related Factors.

---

We retrospectively studied 3107 lumbar spine MRIs in Eastern China to investigate the appropriateness of lumbar spine MR use (From January 1<sup>st</sup> to January 31<sup>st</sup> of 2013 - 1369 male and 1738 female patients, age 52.73±16.14 years, range 3 to 100 years) underwent lumbar MR imaging at the included 10 hospitals

***Only 41.3% of all lumbar spine MR studies were considered as potentially clinically positive diagnosis. Findings of the remaining 58.3% lumbar spine MRIs were regarded as clinically negative. Normal lumbar spine is the most common diagnosis (32.7%) on lumbar spine MRIs, followed by lumbar disc bulging (26.2%) and lumbar disc herniation (15.0%)***



<http://journals.plos.org/plosone/article?id=10.1371/journal.pone.0146369>  
Liedao Yu, Xuanwei Wang, Xiangjin Lin, Yue Wang, Pub Jan 2016

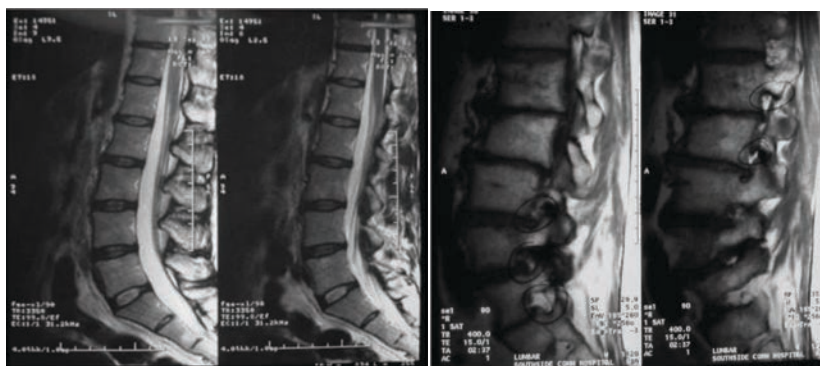MRIs were not predictive of the development or duration of low-back pain. Individuals with the longest duration of low-back pain did not have the greatest degree of anatomical abnormality on prior scans. Clinical correlation is essential to determine the importance of abnormalities on magnetic resonance images.

*.... 77 asymptomatic individuals with no history of back pain underwent magnetic resonance imaging of the lumbar spine. 21 subjects (31%) had an identifiable abnormality of a disc or of the spinal canal. In the current study, we investigated whether the findings on the scans of the lumbar spine that had been made in 1989 predicted the development of low-back pain in these asymptomatic subjects.*



- Borenstein DG, O'Mara JW Jr, Boden SD, Lauerman WC, et. al., The value of magnetic resonance imaging of the lumbar spine to predict low-back pain in asymptomatic subjects: a seven-year follow-up study. J Bone Joint Surg Am. 2001 Sep;83-A(9):1306-11. (PMID: 11568190)

## Over Reliance Upon Technology



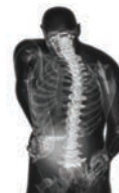- Inflammation of a nerve root is quite painful and does not show up on an MRI or other imaging studies



## Miscellaneous Consideration

---

“Among workers with LBP, early MRI is not associated with better health outcomes and is associated with increased likelihood of disability and its duration.”



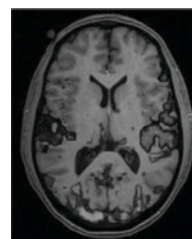
Graves, Janessa M, Fulton-Kehoe, Deborah; Jarvik, Jeffrey G, Franklin, et. al., Early Imaging for Acute Low Back Pain: One-Year Health and Disability Outcomes Among Washington State Workers, Spine. 37(18):1617-1627, August 15, 2012.

**PainWeek**

## fMRI

---

To see how well fMRI could do at measuring pain, the authors evaluated an fMRI-based measure of pain intensity across four studies with 114 total healthy participants.



The authors felt that it may be possible to assess and differentiate pain through an fMRI scan

Wager TD, et al "An fMRI-based neurologic signature of physical pain" *N Engl J Med* 2013; 368(15): 1388-1397; DOI: 10.1056/NEJMoa1204471.

**PainWeek**

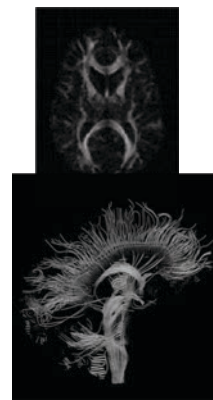
## Diffusor Tensor Imaging dMRI

---

Maps diffusion process of molecules (water) in biological tissues.

Provides the ability to visualize anatomical connections between different parts of the brain.

Combined with fMRI (DfMRI) may be able to generate images of neuronal activation of the brain.



Hagmann et al. "Understanding Diffusion MR Imaging Techniques: From Scalar Diffusion-weighted Imaging to Diffusion Tensor Imaging and Beyond,"  
RadioGraphics. Oct 2006.

**PainWeek**

## CT - Computed Tomography

---

- Earlier referred to as CAT (computed axial tomography) scan, employs tomography. Digital geometry processing is used to generate a 3D image of the inside of an object from a large series of 2D x-rays images taken around a single axis of rotation.
- Has become the gold standard for diagnosis of a large number of different diseases or pathologies.

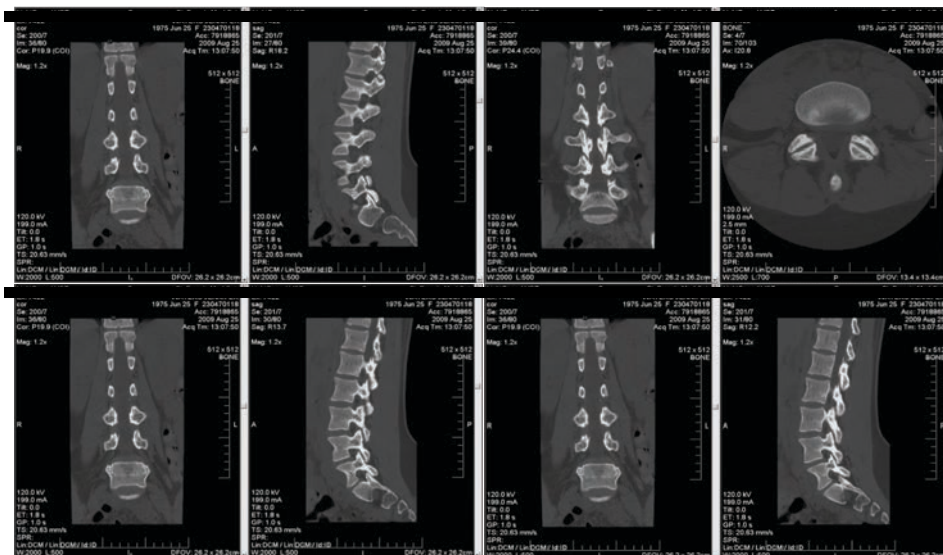**PainWeek**



## CT - Advantages over traditional radiography

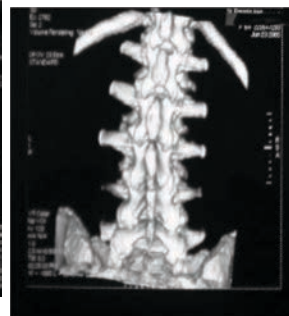
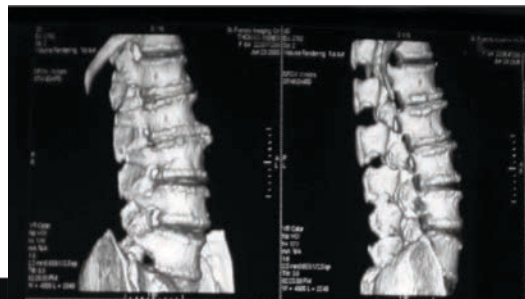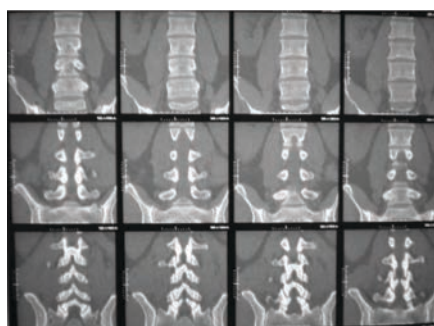
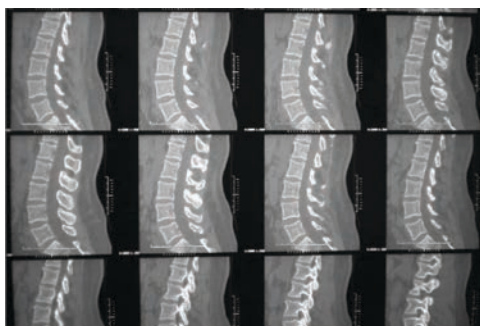
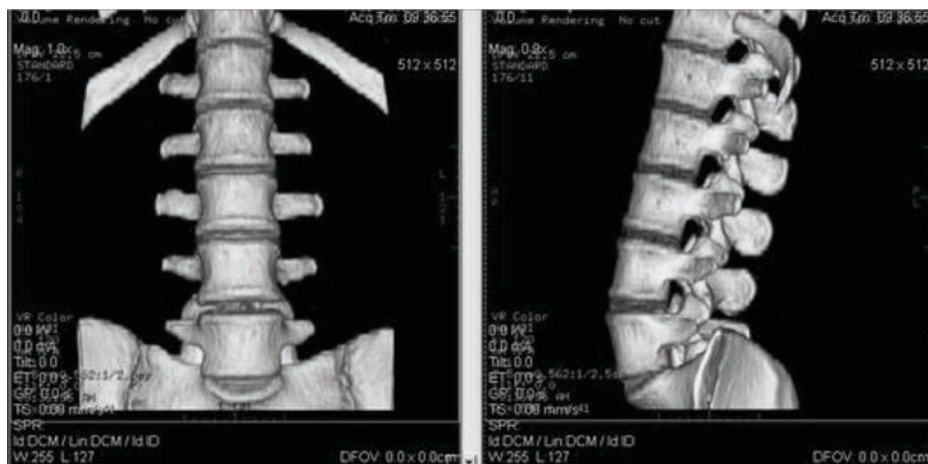
- CT completely eliminates the superimposition of images of structures outside the area of interest.
- Since CT inherently demonstrates high-contrast resolution, differences between tissues that differ in physical density by less than 1% can be distinguished.
- Data from a single CT imaging procedure can be viewed as images in the axial, coronal, or sagittal planes.

**Painweek**



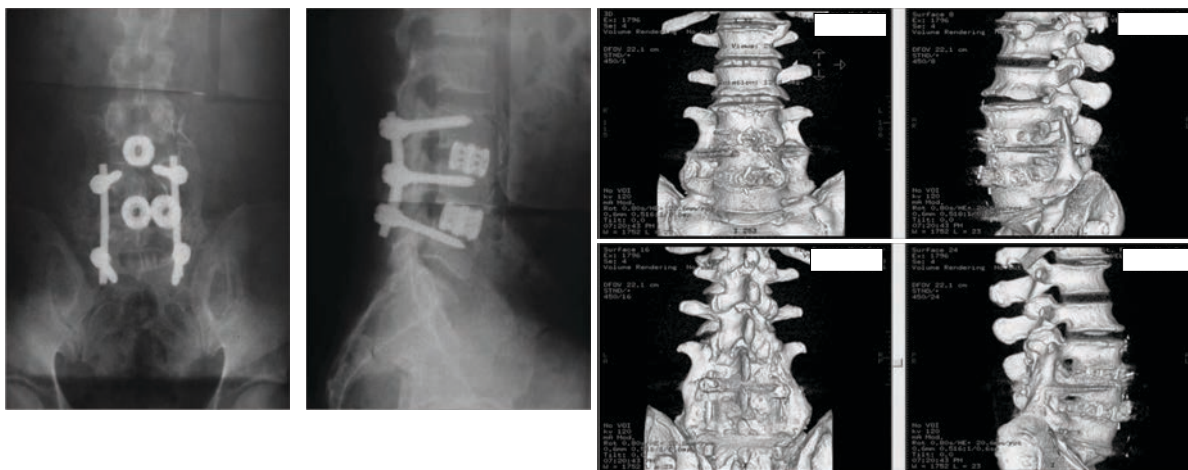
**Painweek**

# CT with 3D Reconstruction

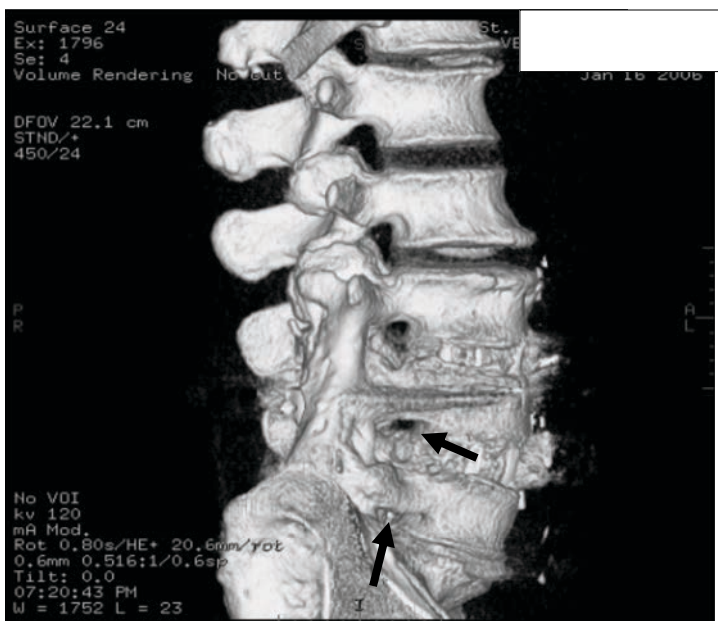


**PainWeek**

# X-ray vs. CT



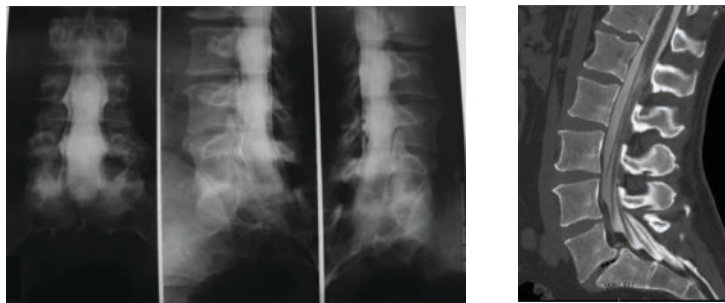**PainWeek.**



**PainWeek.**

## CT Myelogram

- Address a limitation of CT to assess neural structures in the spine by combining with Myelography (injecting radiographic contrast into the spinal canal (CSF) to help illuminate the spinal canal, cord, and nerve roots during imaging, particularly sensitive at detecting small herniations resulting in root compression).
- Often ordered by surgeons for operative planning or as a substitute for MRI imaging for patients who cannot have an MRI.



**PainWeek**

## Bone Scan

- A nuclear scanning test that can identify areas of new bone growth or destruction. It can be done to evaluate damage to the bones, find cancer that has spread (metastasized) to the bones, and monitor conditions that can affect the bones (including infection and trauma).
- A bone scan can often find a pathology days to months earlier than a regular X-ray test.

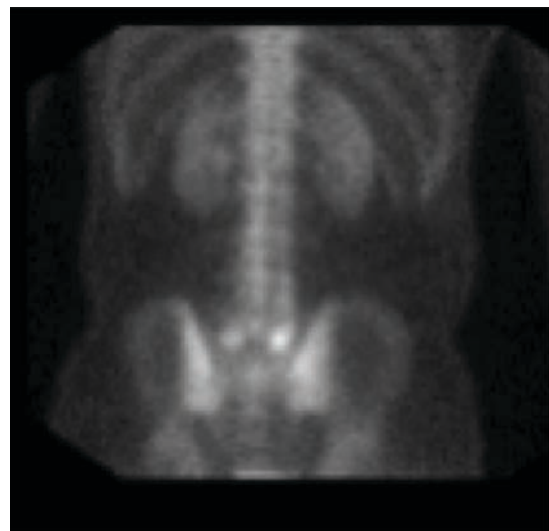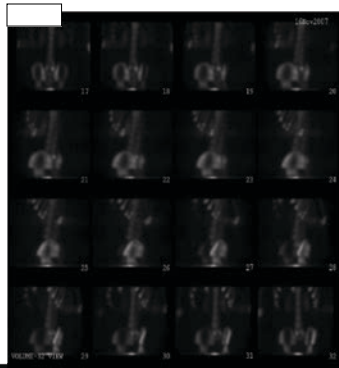
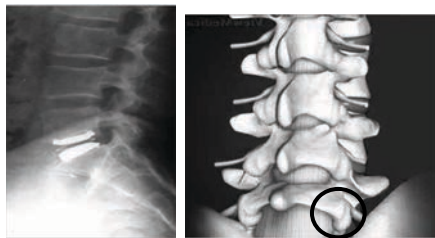
**PainWeek**

Fischbach FT, Dunning MB III, eds. Manual of Laboratory and Diagnostic Tests, 8th ed. Philadelphia: Lippincott Williams and Wilkins, 2009.

## Bone Scan

- Radioactive tracer is injected into the patient. After 2-5 hours, a gamma camera is then used to image the body.
- Abnormalities are identified by “hot spots” and “cold spots.”
  - Hot – accumulation of tracer caused by a fracture that is healing, bone cancer, a bone infection or a disease of abnormal bone metabolism.
  - Cold - certain type of cancer (such as multiple myeloma) or bone infarction.

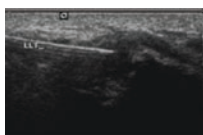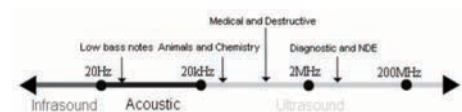
**PainWeek.**



**PainWeek.**

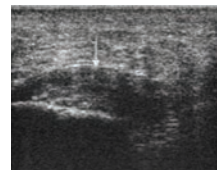
## Ultrasound

- **Ultrasound** is cyclic sound pressure with a frequency greater than the upper limit of human hearing
- Can capture size and structure of anatomical structures or pathological lesions in real time



AC Joint injection

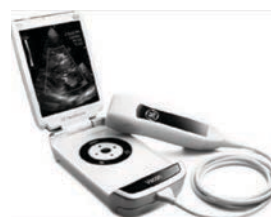Thickened plantar fascia insertion



**PainWeek**

## Handheld Technology

- **Handheld Diagnostic Ultrasound**
  - black and white anatomic and color-coded blood flow images in real-time
  - heart, abdominal organs, urinary bladder and will provide insights in areas of Ob/Gyn, pleural fluid, motion detection and pediatrics



**PainWeek**

## Clinical Pearls for EMG

---

- Pre-ganglionic sensory radiculopathies cannot be identified by classic EMG/NCV.
- Cookie-cutter studies are very limited in their ability to identify pathology by being narrowly focused. In this regard, tailoring the study to the patient can significantly increase diagnostic yield.



Delisa JA, et. al., Manual of Nerve Conduction Velocity and Clinical Neurophysiology, Raven Press, 1994.

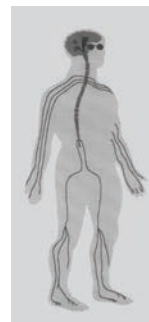## Somatosensory Evoked Potentials (SEPs)

---

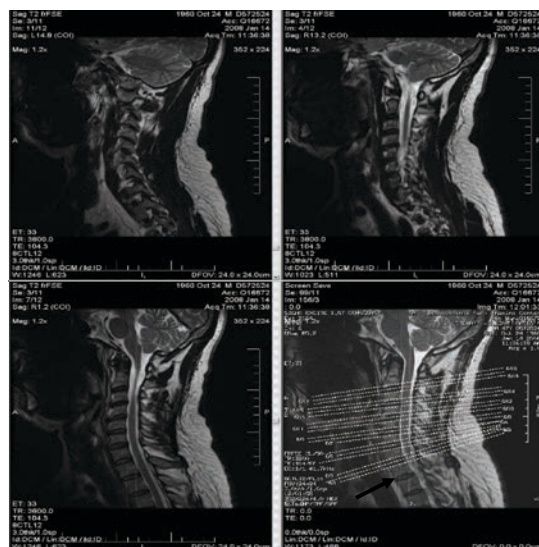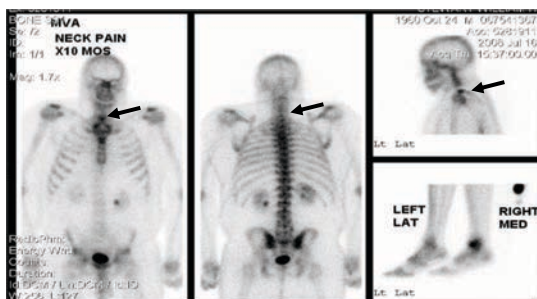
*SSEP*: “Short latency” SEP—Portion of test results that occur within 25 msec for the upper extremities, 50 msec for the lower.

*Dermatomal (or DSEPs)*: Responses generated when stimulating a dermatome.

*Segmental SEPs*: Responses generated when stimulating a nerve with a primary innervation of one nerve root.



- X-ray – Unremarkable
- MRI – Mild DJD C3/C4, C4/C5
- EMG – Pt could not tolerate
- SEP – T1 Radiculitis
- Bone Scan – Inconclusive



**PainWeek**

## Take Home Message

- The reliability or the clinical relevance of any diagnostic procedure is never 100%.
- The studies themselves may be deficient in that particular clinical situation.
  - Inadequately structured for that particular patient.
  - Adversely effected by other influences (technical considerations).
- Objective clinical examination findings should not be dismissed based solely upon negative test results.

**PainWeek**