

PainWEEK

Clinical Pearls: Unraveling the Secrets of Imaging Studies

David M. Glick, DC, DAAPM, CPE

© 2019 PainWeek LLC

Conflict of Interest and Disclosures

- Nothing to Disclose

PainWEEK

Course Objectives

- Identify basic imaging studies used for the diagnosis of pain disorders
- Describe the clinical utility and limitations of such studies for the differential diagnosis of pain pathologies
- Explain strategies to enhance the clinical yield of imaging studies

PainWEEK

When More Medicine is Less

- Nine United States specialty societies representing 374,000 physicians developed lists of *Five Things Physicians and Patients Should Question*

- [American Academy of Allergy, Asthma & Immunology](#)
- [American Academy of Family Physicians](#)
- [American College of Cardiology](#)
- [American College of Physicians](#)
- [American College of Radiology](#)
- [American Geriatrics Society](#)
- [American Society of Clinical Oncology](#)
- [American Society of Nephrology](#)
- [American Society of Nuclear Cardiology](#)

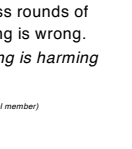


Choosing Wisely
American Academy of Family Physicians
Five Things Physicians and Patients Should Question

painweek http://choosingwisely.org/?page_id=13

**Choosing Wisely
(Initiative of ABIM Foundation):**

- Not only are many procedures unnecessary, some are actually harmful and can lead to mistaken diagnosis or endless rounds of follow-up testing when nothing is wrong.
- *“Over testing and over treating is harming people and unethical.”*
*(Dr. Glen Stream, President
American Academy of Family Practice Physicians & Panel member)*




Choosing Wisely
American Academy of Family Physicians
Five Things Physicians and Patients Should Question

painweek http://choosingwisely.org/?page_id=13

Medical Necessity of Imaging for LBP

- Low back pain is the fifth most common reason for all physician visits.
- Don't do imaging for low back pain within the first six weeks, unless red flags are present.
 - Red flags include, but are not limited to, severe or progressive neurological deficits or when serious underlying conditions such as osteomyelitis are suspected. Imaging of the lower spine before six weeks does not improve outcomes, but does increase costs.




Choosing Wisely
American Academy of Family Physicians
Five Things Physicians and Patients Should Question

painweek http://choosingwisely.org/?page_id=13

MRIs and CT Scans for Headaches

- Don't do imaging for uncomplicated headache.

"Imaging headache patients absent specific risk factors (such as loss of vision, seizures, etc) for structural disease is not likely to change management or improve outcome. Those patients with a significant likelihood of structural disease requiring immediate attention are detected by clinical screens that have been validated in many settings. Many studies and clinical practice guidelines concur. Also, incidental findings lead to additional medical procedures and expense that do not improve patient well-being."



PainWeek http://choosingwisely.org/?page_id=13

Choosing Wisely Update

- 72 societies and 17 community groups have joined the initiative
- Over 450 recommendations (over 66 lists)
- Hundreds of potentially unnecessary medical tests and treatments have been identified to date
- Several societies have released 2nd and 3rd lists
- Estimated 5 billion in potential savings for unnecessary testing
- 400 main stream articles/20,000 blogs or Pt stories about unnecessary tests or treatments

PainWeek

Choosing Wisely Update (cont'd)

Figure 5: In your own practice, is this a reason you sometimes end up ordering an unnecessary test or procedure? (N=1,718, is this a major reason or minor reason?)

PainWeek http://www.choosingwisely.org/wp-content/uploads/2014/04/042814_Final-Choosing-Wisely-Survey-Report.pdf

Most Important Tools for Differential Diagnosis...

- History
- Clinical Examination
- Experience of Clinician



Adverse Factors Affecting Physical Diagnosis

- Limitations of time
 - Volume of patients may limit face-to-face time with clinician
 - Reimbursements tend to devalue clinical component
- Reliance upon technology
 - MRI shows disc herniations so that must be the cause of the patient's neck pain.
- Clinical experience
 - Has the clinician evaluated patients with similar symptoms before

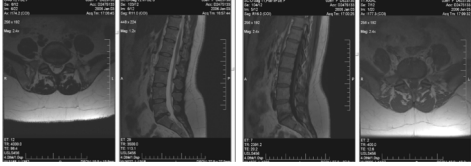


MRI—Magnetic Resonance Imaging

- Uses a powerful magnetic field to align the hydrogen atoms in water in the body. Radio frequency (RF) fields are used to energize hydrogen nuclei (protons). When the field is turned off, energy is released as the protons return to their resting state. This energy is recorded by the scanner. The position of protons in the body can be determined by applying additional magnetic fields (using gradient coils) during the scan, which allows an image of the body to be created.
- Contrast between different types of body tissue is created by changing the parameters on the scanner. Diseased tissue, such as tumors, can be detected because the protons in different tissues return to their equilibrium state at different rates.



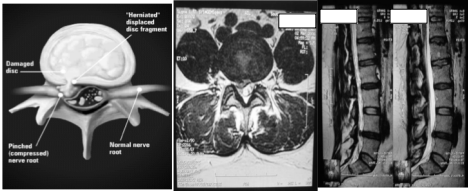
Novelline, Robert, Swain's Fundamentals of Radiology, Harvard University Press, 5th edition, 1997



- On a T2-weighted scan, water- and fluid-containing tissues are bright and fat-containing tissues are dark, the reverse is true for T1
- Damaged tissue tends to develop edema, which makes a T2-weighted sequence sensitive for pathology

PainWeek


Nerve Root Compression



PainWeek

Image © Swam Interactive www.swaminteractive.com

Putting Knowledge to the Test...



Surgical or non-surgical?
Axial back pain without radicular symptoms


PainWeek

Which patient is suffering from severe chronic low back pain?

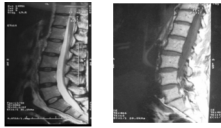


painweek
Image © Swam Interactive www.swaminteractive.com

Clinical Pearl



MRI may demonstrate disc compression of a nerve, but current technology **does not** describe inflammation of a nerve (radiculitis)



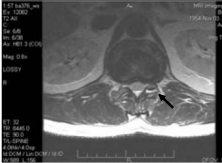
Which patient is suffering from severe chronic low back pain?

While providing valuable structural, they do not necessarily reflect whether a pathology is clinically relevant

painweek
Image © Swam Interactive www.swaminteractive.com

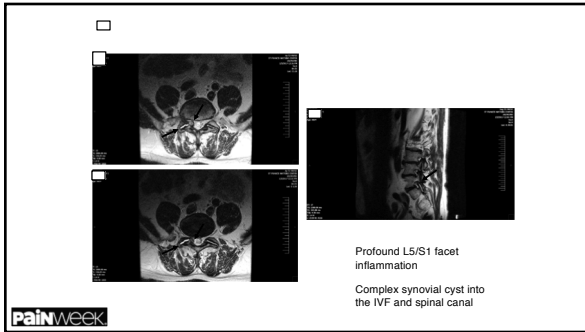
Clinical Pearl (cont'd)

Facet joint inflammation



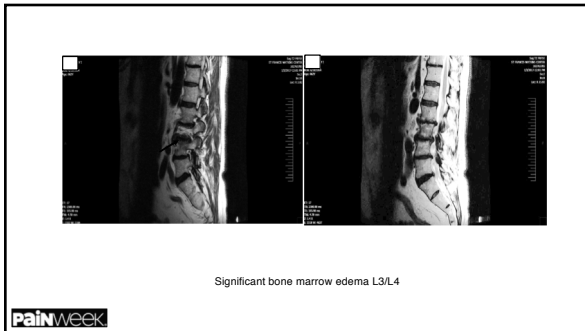
The individual reading the MRI or other imaging study is often not clinically familiar with the patient

painweek




Profound L5/S1 facet inflammation
Complex synovial cyst into the IVF and spinal canal

PainWeek

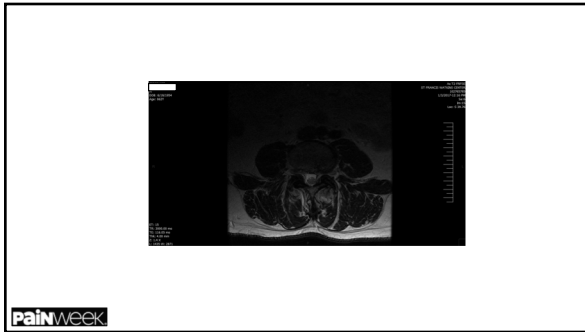


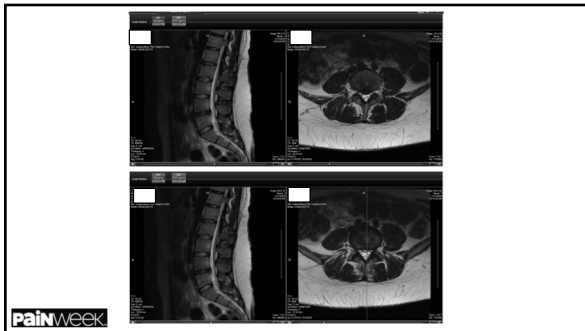
Significant bone marrow edema L3/L4

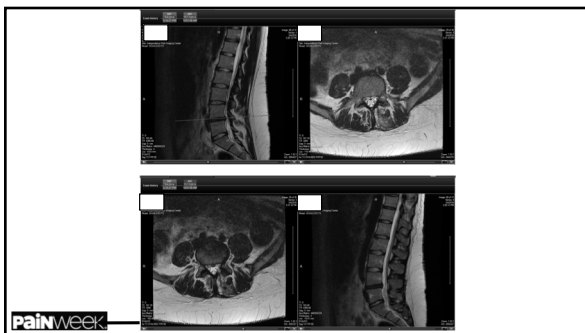
PainWeek



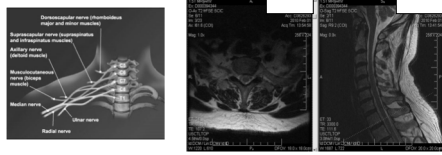
PainWeek







Clinical Pearl (cont'd) Always request axial images to include C8 & T1 roots on order for cervical MRI



- Brachial plexus is C5-T1 spinal nerve roots
- All intrinsic muscles of the hand are innervated by C8/T1, as are most muscles for grip
- If upper extremity symptoms extend to hand or include decrease grip strength, then there is a high likelihood C8 or T1 is involved
- Most cervical MRIs do not image the T1 root, and many do not include C8

PainWeek
Brachial plexus image © Medcom studies - Beere Oonoon www.medcomstudies.com

MRI of the lumbar spine in people without back pain.

On MRI examination of the lumbar spine, many people without back pain have disc bulges or protrusions but not extrusions. Given the high prevalence of these findings and of back pain, the discovery by MRI of bulges or protrusions in people with low back pain may frequently be coincidental.

.... Thirty-six percent of the 98 asymptomatic subjects had normal discs at all levels. With the results of the two readings averaged, 52% of the subjects had a bulge at least one level, 27% had a protrusion, and 1% had an extrusion. 38% had an abnormality of more than one intervertebral disc.

PainWeek
Jensen MC, Brant-Zawadzki MN, Obuchowski N, Modic MT, et al. Magnetic resonance imaging of the lumbar spine in people without back pain. N Engl J Med. 1994 Jul 14;331(2):69-73. (PMID: 8208267)

The Use of Lumbar Spine Magnetic Resonance Imaging in Eastern China: Appropriateness and Related Factors.

We retrospectively studied 3107 lumbar spine MRIs in Eastern China to investigate the appropriateness of lumbar spine MR use (From January 1st to January 31st of 2013: 1369 male and 1738 female patients, age 52.73±16.14 years, range 3 to 100 years) underwent lumbar MR imaging at the included 10 hospitals

Only 41.3% of all lumbar spine MR studies were considered as potentially clinically positive diagnosis. Findings of the remaining 58.3% lumbar spine MRIs were regarded as clinically negative. Normal lumbar spine is the most common diagnosis (32.7%) on lumbar spine MRIs, followed by lumbar disc bulging (26.2%) and lumbar disc herniation (15.0%)

PainWeek
<http://journals.plos.com/plosone/article?id=10.1371/journal.pone.0146369>
 Liedo Yu, Xuanwei Wang, Xianglin Lin, Yue Wang, Pub Jan 2016

MRI of the lumbar spine in people without back pain.

- 148 asymptomatic subjects - 69 (46%) had never experienced low back pain
- 123 subjects (83%) with moderate to severe desiccation of one or more discs
- 83 (56%) with loss of disc height
- 48 subjects (32%) had at least one disc protrusion
- 9 (6%) had one or more disc extrusions ¹

Armed with an interesting application of the Jarvik data, when including the epidemiological information with the MR imaging reports McCullough's group cited a slightly lowered incidence of opioid prescriptions, physical therapy and repeat injections. ² Clearly utilization may have been affected, there was however no information concerning treatment outcomes.



1. Jarvik JJ, Hollingworth W, Heagerty P, Haynor DR, Deyo RA. The Longitudinal Assessment of Imaging and Disability of the Back (LADiBack) Study: baseline data. *Spine (Phila Pa 1976)*. 2001;26(10):1158-1166.
 2. McCullough BJ, Johnson GR, Martin BI, Jarvik JG. Lumbar MR imaging and reporting epidemiology: do epidemiologic data in reports affect clinical management?. *Radiology*. 2012;262(3):941-6.

The value of magnetic resonance imaging of the lumbar spine to predict low-back pain in asymptomatic subjects

MRIs were not predictive of the development or duration of low-back pain. Individuals with the longest duration of low-back pain did not have the greatest degree of anatomical abnormality on prior scans. Clinical correlation is essential to determine the importance of abnormalities on magnetic resonance images.

... 77 asymptomatic individuals with no history of back pain underwent magnetic resonance imaging of the lumbar spine. 21 subjects (31%) had an identifiable abnormality of a disc or of the spinal canal. In the current study, we investigated whether the findings on the scans of the lumbar spine that had been made in 1989 predicted the development of low-back pain in these asymptomatic subjects.



Borenstein DG, OMara JW Jr, Boden SD, Lauerman WC, et al. The value of magnetic resonance imaging of the lumbar spine to predict low-back pain in asymptomatic subjects: a seven-year follow-up study. *J Bone Joint Surg Am*. 2001 Sep;83-A(9):1306-11. (PMID: 11568190)

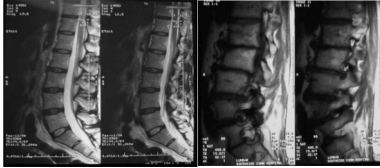MRI of cervical intervertebral discs in asymptomatic subjects

- 497 **asymptomatic** subjects evaluated by cervical MRI
- Frequency of all degenerative findings increased linearly with age
- Disc degeneration was the most common observation
 - 17% males / 12% females in their twenties
 - **86% male / 89% females over 60 years of age**
- Significant differences in frequency between genders for posterior disc protrusion and foraminal stenosis
- 7.6% of subjects over 50 were identified as having cord compression



MRI of cervical intervertebral discs in asymptomatic subjects. Matsumoto M¹, Fujimura Y, Suzuki N, Nishi Y, Nakamura M, Yabe Y, Shiga H. *J Bone Joint Surg Br*. 1998 Jan;80(1):19-24.

Over Reliance Upon Technology



Inflammation of a nerve root is quite painful and does not show up on an MRI or other imaging studies

PainWeek

Miscellaneous Consideration

"Among workers with LBP, early MRI is not associated with better health outcomes and is associated with increased likelihood of disability and its duration."

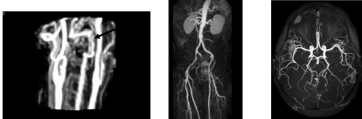


Graves, Janessa M, Fulton-Kehoe, Deborah; Jarvik, Jeffrey G, Franklin, et. al., Early Imaging for Acute Low Back Pain: One-Year Health and Disability Outcomes Among Washington State Workers, Spine. 37(18):1617-1627, August 15, 2012.

PainWeek

MRA – Magnetic Resonance Angiography

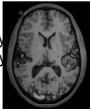
- Generate pictures of the arteries in order to evaluate them for stenosis or aneurysms with the use of contrast or flow-related enhancement
- MRA is often used to evaluate the arteries of the neck and brain, the thoracic and abdominal aorta, the renal arteries, and the legs



PainWeek

fMRI

- To see how well fMRI could do at measuring pain, the authors evaluated an fMRI-based measure of pain intensity across four studies with 114 total healthy participants
- The authors felt that it may be possible to assess and differentiate pain through an fMRI scan

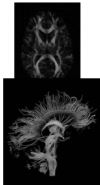


Wager TD, et al "An fMRI-based neurologic signature of physical pain" *N Engl J Med* 2013; 368(15): 1388-1397. DOI: 10.1056/NEJMoa1204471

PainWeek

Diffusor Tensor Imaging dMRI

- Maps diffusion process of molecules (water) in biological tissues
- Provides the ability to visualize anatomical connections between different parts of the brain
- Combined with fMRI (DMRI) may be able to generate images of neuronal activation of the brain



Haemmann et al. "Understanding Diffusion MRI Imaging Techniques: From Scalar Diffusion-weighted Imaging to Diffusion Tensor Imaging and Beyond" *RadioGraphics*. Oct 2006

PainWeek

CT—Computed Tomography

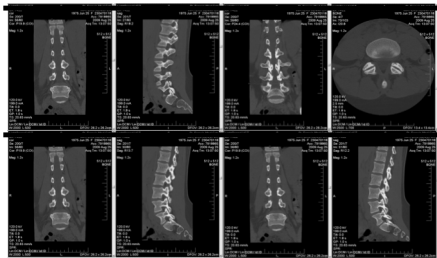
- Earlier referred to as CAT (computed axial tomography) scan, employs tomography. Digital geometry processing is used to generate a 3D image of the inside of an object from a large series of 2D x-rays images taken around a single axis of rotation
- Has become the gold standard for diagnosis of a large number of different diseases or pathologies

PainWeek

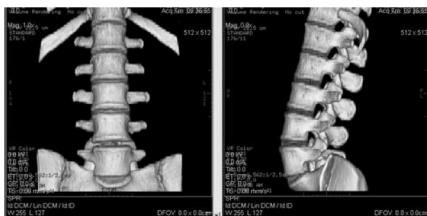CT – Advantages Over Traditional Radiography

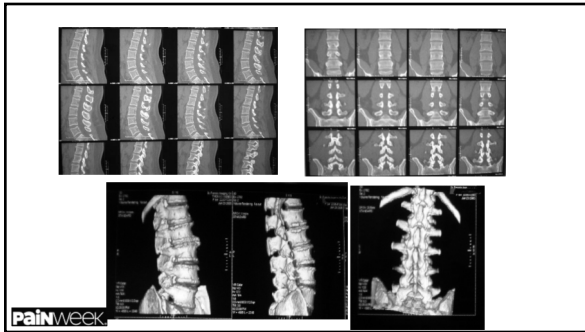
- CT completely eliminates the superimposition of images of structures outside the area of interest
- Since CT inherently demonstrates high-contrast resolution, differences between tissues that differ in physical density by less than 1% can be distinguished
- Data from a single CT imaging procedure can be viewed as images in the axial, coronal, or sagittal planes

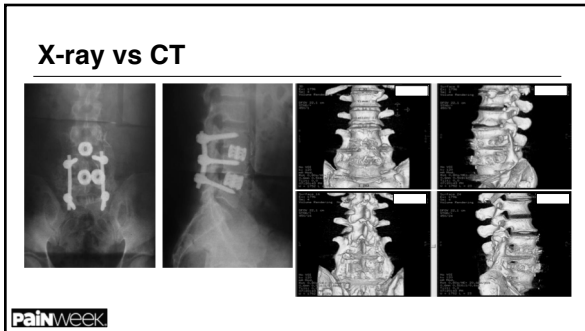


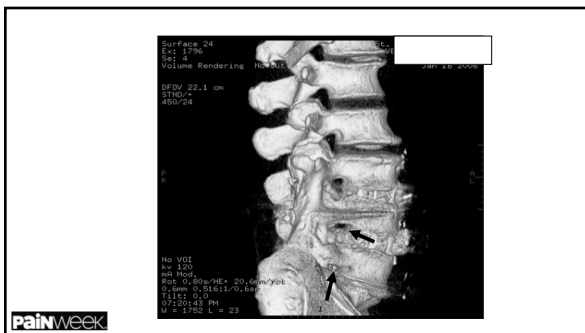

CT with 3D Reconstruction



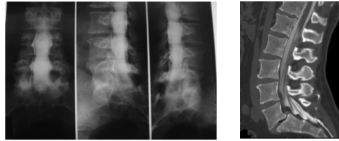






CT Myelogram

- Address a limitation of CT to assess neural structures in the spine by combining with Myelography (injecting radiographic contrast into the spinal canal (CSF) to help illuminate the spinal canal, cord, and nerve roots during imaging, particularly sensitive at detecting small herniations resulting in root compression)
- Often ordered by surgeons for operative planning or as a substitute for MRI imaging for patients who cannot have an MRI



PainWeek

Bone Scan

- A nuclear scanning test that can identify areas of new bone growth or destruction. It can be done to evaluate damage to the bones, find cancer that has spread (metastasized) to the bones, and monitor conditions that can affect the bones (including infection and trauma)
- A bone scan can often find a pathology days to months earlier than a regular X-ray test

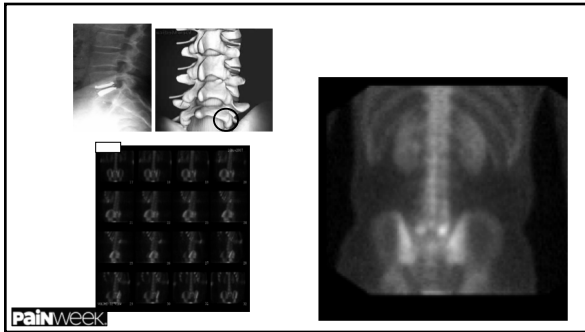
PainWeek

Fischbach FT, Dunning MB III, eds. Manual of Laboratory and Diagnostic Tests, 8th ed. Philadelphia: Lippincott Williams and Wilkins, 2009.

Bone Scan

- Radioactive tracer is injected into the patient. After 2-5 hours, a gamma camera is then used to image the body
- Abnormalities are identified by "hot spots" and "cold spots"
 - Hot—accumulation of tracer caused by a fracture that is healing, bone cancer, a bone infection or a disease of abnormal bone metabolism
 - Cold—certain type of cancer (such as multiple myeloma) or bone infarction

PainWeek



Ultrasound

- **Ultrasound** is cyclic sound pressure with a frequency greater than the upper limit of human hearing
- Can capture size and structure of anatomical structures or pathological lesions in real time

The diagram shows a frequency spectrum from 0 to 2000 Hz. The range from 0 to 20,000 Hz is labeled 'Hearing'. The range from 20,000 Hz to 10,000,000 Hz is labeled 'Medical and Diagnostic'. Within the medical range, '200 Hz' is marked for 'Litt. for research, Arthroscopy and CT scans', '2000 Hz' for 'Acoustic', '20,000 Hz' for 'Diagnostic and ICD', and '200,000 Hz' for 'Lithotripsy'. Below the diagram are two ultrasound images: one labeled 'AC Joint injection' and another labeled 'Thickened plantar fascia insertion'.

PainWeek

Handheld Technology

- Handheld diagnostic ultrasound
 - Black and white anatomic and color-coded blood flow images in real-time
 - Heart, abdominal organs, urinary bladder and will provide insights in areas of Ob/Gyn, pleural fluid, motion detection and pediatrics

The image shows a handheld ultrasound device on the left and a person using it on the right. The person is holding the device against their chest, and a small screen on the device displays an ultrasound image.

PainWeek

Take Home Message

- The reliability or the clinical relevance of any diagnostic procedure is never 100%
- The studies themselves may be deficient in that particular clinical situation
 - Inadequately structured for that particular patient
 - Adversely effected by other influences (technical considerations)
- Objective clinical examination findings should not be dismissed based solely upon negative test results